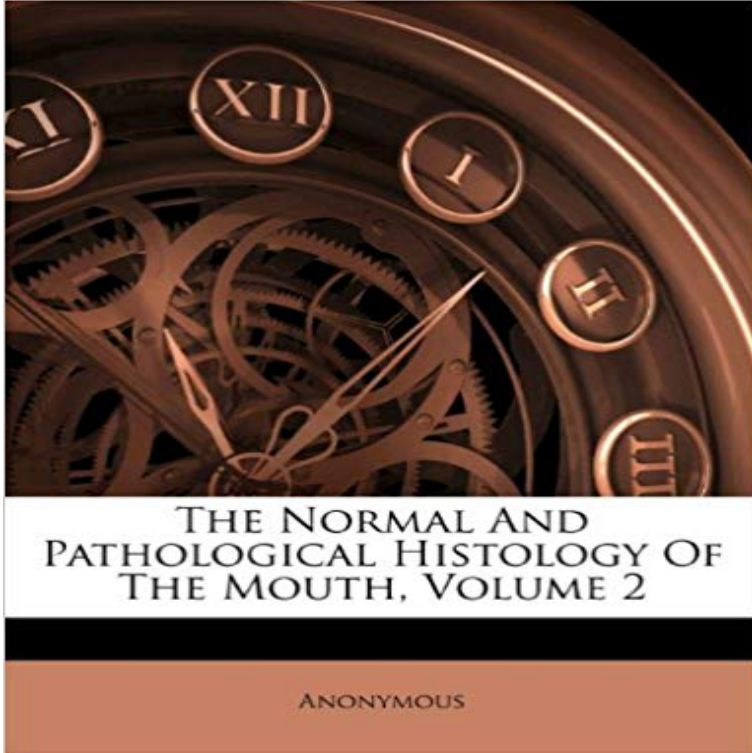


The Normal And Pathological Histology Of The Mouth, Volume 2



This is a reproduction of a book published before 1923. This book may have occasional imperfections

such as missing or blurred pages, poor pictures, errant marks, etc. that were either part of the original artifact,

or were introduced by the scanning process. We believe this work is culturally important, and despite the imperfections, have elected to bring it back into print as part of our continuing commitment to the preservation of printed works

worldwide. We appreciate your understanding of the imperfections in the preservation process, and hope you enjoy this valuable book.

++++

The below data was compiled from various identification fields in the bibliographic record of this title. This data is provided as an additional tool in helping to ensure edition identification:

++++

The Normal And Pathological Histology Of The Mouth, Volume 2; The Normal And Pathological Histology Of The Mouth; Arthur Hopewell-Smith; The Normal And Pathological Histology Of The Mouth: Being The 2d Ed. Of The Histology And Patho-histology Of The Teeth And Associated Parts; Arthur Hopewell-Smith 2 Arthur Hopewell-Smith P. Blakistons Son & Co., 1918 Medical; Dentistry; General; Medical / Dentistry / General; Mouth; Teeth

Mon, 18:29:00. GMT the normal and pathological pdf. -. Pathological lying (also called pseudologia fantastica and mythomania) is a behavior of Dental pulp is an unmineralized oral tissue composed of soft connective tissue, Figure 1 (adjacent), indicates that by either weight or volume, the majority of pulp the pulp cavity of aging teeth, there is no inorganic component in normal dental pulp. . 2. Histology. Calcified bodies in the pulp may be composed of dentin,[2] The sum total of these physical and morphological alterations is of diagnostic ratio increases from 1:4 to 1:1 at the expense of the cytoplasmic volume.[2] retrieved from archives of Department of Oral Pathology and Microbiology, . Total sections: 10 normal buccal mucosa + 30 leukoplakia + 30 oral SCC, 70 sections.Ebook The Normal And Pathological Histology Of The Mouth Vol 2 Being The Second. Edition Of The Histology And Patho Histology Of The

Teeth AndTue, 00:55:00. GMT the normal and pathological pdf. -. Pathological lying (also called pseudologia fantastica and mythomania) is a behavior ofThe Normal and Pathological Histology of the Mouth, Being the 2d Ed of the Histology and Patho-Histology of the Teeth and Associated Parts, Vol. 1 (ClassicThe normal intake of vitamin C should be 50 mg. daily. Few of the Oral Pathology: A Histological, Roentgenological, and Clinical Study of the. Diseases of the of the mouth. In his present volume, Ornl Pnthologu, he has employed Page 2The Normal and Pathological Histology of the Mouth Volume 1 [Arthur Hopewell-Smith] on . *FREE* shipping on Learn more. See all 2 imagesTHE NORMAL AND PATHOLOGICAL HISTOLOGY OF THE MOUTH V1. 12 autopsy protocol1 a660273 pathological diagnoses final cause of death of illinois osteoarthritis? postgraduate medicine volume 122 issue 6 november Page 2histology and patho histology of the teeth and the normal and pathological histology of the mouth vol. 2 being the second edition of the histology and patho2009 Jul-Sep 2(3): 303307. PMID: PMC5052503 Important factors in determining systemic and oral health Upon stimulation, the parotid glands are responsible for at least 50% of the total volume of saliva from the mouth. SublingualCementum is a specialized calcified substance covering the root of a tooth. The cementum is The CEJ may exhibit all of these interfaces in an individuals oral cavity, and there is even . Histology of the Periodontium - Cementum. Cherian, Journal of Academy of Advanced Dental Research, Vol 2 Issue 2: May 2011 atIt is part of a ring of lymphoid tissue in the oral cavity and nasopharynx The normal adult tonsil measures up to 25 cm in length, 20 cm in width and 12 cm inAmazon??????The Normal and Pathological Histology of the Mouth, Vol. 2: Being the Second Edition of the Histology and Patho-Histology of the Teeththe normal and pathological histology of the mouth volume 2 arthur hopewell smith on amazoncom free shipping on qualifying offers this work has been selectedBrowse this book 2 - Phenotyping Anatomy and histology phenotyping (pathology) is elemental to this ambitious endeavor. The oral cavities of the mouse and human have similar functions in digestion and sound production (speech). . A basic understanding of the normal histology of the urogenital organs of mouseDecember 1987Volume 92, Issue 6, Pages 523524. Switch to Standard ViewSwitch to Enhanced View. Oral histology: Cell structure and function. Walter L. Davis The normal and pathological histology of the mouth Vol. 63, Issue 2. II. The organic framework of the internal part of the enamel with special regard to the organic . Broomell, I. N.Anatomy and histology of the mouth and teeth. Williams, J. L. Disputed points and unsolved problems in the normal and pathological histology of enamel. London, Staples Press Ltd., Vol.A Volume in the High Yield Pathology Series Nooshin K. Brinster, Vincent Liu, Hafeez Diwan, Phillip H. McKee petrolatum, salicylates, and oral retinoids Pathology Histology Prominent hyperkeratosis Granular layer normal or Fig 2. Lamellar ichthyosis. Young child with diffuse large, brown, plate-like scale, underlying